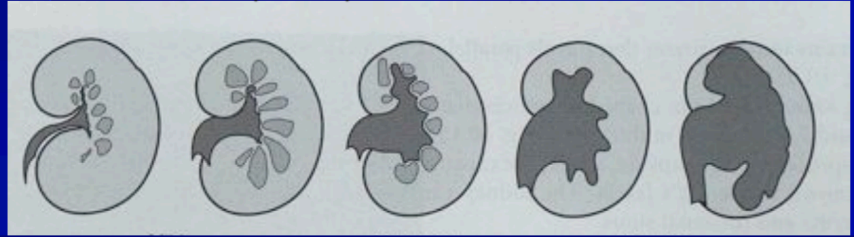


Area of interest	PoCUS – Measurements and Quick Reference
Abdominal Aorta	Normal = <3cm diameter
Renal	<p>Degrees of hydronephrosis Mild - Minimal separation of calyces Moderate - Dilation of major and minor calyceal system Severe - Marked dilation of the renal pelvis, thinning of parenchyma</p>  <p style="text-align: center;">Normal Mild Moderate Severe Hydronephrosis</p>
Gallbladder	<p>Width: 40-50mm Wall thickness: Average 2-3mm Pathologic >3.5 mm CBD: Normal 4mm (<6mm)</p> <ul style="list-style-type: none"> • Age dependent CBD diameter change (Normal size in mm roughly equals age in decades) • 8-10mm after cholecystectomy may be normal
Bladder	<p>Width: Normal empty bladder <5mm</p> <ul style="list-style-type: none"> • Distended bladder <3mm <p>Post void residual <100-150ml</p>
Optic nerve	Diameter: Normal < 5mm (measured 3mm posterior to globe)
Appendix	<p>Features of a normal appendix:</p> <ul style="list-style-type: none"> • Compressible, blind-ended tubular structure • Surrounded by normal appearing fat • Wall thickness <3mm (serosa to lumen) • Diameter<6mm (serosa to serosa) <p>Features of appendicitis:</p> <ul style="list-style-type: none"> • Characterized by wall thickness >3mm, diameter>6mm. • Hypervascular wall with color Doppler, • Free fluid and presence of appendicolith are secondary signs.
Small Bowel	<p>SBO: ≥3 loops dilated (>25 mm), non-compressible small bowel proximal to collapsed, compressible bowel Secondary signs: localized bowel wall edema (>3 mm thick), free fluid between bowel loops (Tanga sign), abnormal peristalsis (to and fro peristalsis)</p>

Area of interest	PoCUS – Measurements and Quick Reference																	
MSK:	Tendinopathy: Normal Achilles : <6mm measured at level of medial malleolus Patellar Tendon: Normal= 3-4mm Plantar fascia: Plantar fascitiis >4mm																	
Obstetric	<table border="1" data-bbox="448 533 1270 763"> <thead> <tr> <th data-bbox="448 533 719 607">Embryonic structure</th> <th data-bbox="719 533 999 607">Trans Vag U/S</th> <th data-bbox="999 533 1270 607">Trans Abdo U/S</th> </tr> </thead> <tbody> <tr> <td data-bbox="448 607 719 645">Gestational Sac</td> <td data-bbox="719 607 999 645">4.5-5wks</td> <td data-bbox="999 607 1270 645">5.5-6wks</td> </tr> <tr> <td data-bbox="448 645 719 683">Yolk Sac</td> <td data-bbox="719 645 999 683">5-5.5 wks</td> <td data-bbox="999 645 1270 683">6-6.5wks</td> </tr> <tr> <td data-bbox="448 683 719 721">Fetal Pole</td> <td data-bbox="719 683 999 721">5.5-6wks</td> <td data-bbox="999 683 1270 721">6.5-7weeks</td> </tr> <tr> <td data-bbox="448 721 719 759">Fetal Heart Beat</td> <td data-bbox="719 721 999 759">6 wks</td> <td data-bbox="999 721 1270 759">7wks</td> </tr> </tbody> </table> <p data-bbox="448 801 1329 840">Definitive IUP = Yolk Sac and or Fetal Pole inside Gestational Sac</p> <p data-bbox="448 878 1131 916">Level of beta-HCG above which IUP typically seen:</p> <p data-bbox="448 916 815 954">Transvaginal - 1,500-2,000</p> <p data-bbox="448 954 775 992">Transabdominal - 6,500</p>			Embryonic structure	Trans Vag U/S	Trans Abdo U/S	Gestational Sac	4.5-5wks	5.5-6wks	Yolk Sac	5-5.5 wks	6-6.5wks	Fetal Pole	5.5-6wks	6.5-7weeks	Fetal Heart Beat	6 wks	7wks
Embryonic structure	Trans Vag U/S	Trans Abdo U/S																
Gestational Sac	4.5-5wks	5.5-6wks																
Yolk Sac	5-5.5 wks	6-6.5wks																
Fetal Pole	5.5-6wks	6.5-7weeks																
Fetal Heart Beat	6 wks	7wks																
IVC	<p data-bbox="448 1064 1433 1137">IVC collapses slightly on inspiration in spontaneously breathing patient, but collapses on expiration in mechanically ventilated patient</p> <table border="1" data-bbox="448 1176 1441 1570"> <thead> <tr> <th data-bbox="448 1176 644 1323">Maximum IVC Diameter</th> <th data-bbox="644 1176 1155 1323">Collapse Index (%) = 100 x (Max – Min Diameter) / Max Diameter</th> <th data-bbox="1155 1176 1441 1323">Estimated Right Atrial Pressure Estimated filling status</th> </tr> </thead> <tbody> <tr> <td data-bbox="448 1323 644 1458">< 2 cm Small</td> <td data-bbox="644 1323 1155 1458">> 40 to 50% Collapses</td> <td data-bbox="1155 1323 1441 1458">< 10 mmHg Empty (low volume state)</td> </tr> <tr> <td data-bbox="448 1458 644 1570">> 2 cm Dilated</td> <td data-bbox="644 1458 1155 1570">< 40 to 50% No collapse</td> <td data-bbox="1155 1458 1441 1570">> 10 mmHg Full (high filling pressure)</td> </tr> </tbody> </table>			Maximum IVC Diameter	Collapse Index (%) = 100 x (Max – Min Diameter) / Max Diameter	Estimated Right Atrial Pressure Estimated filling status	< 2 cm Small	> 40 to 50% Collapses	< 10 mmHg Empty (low volume state)	> 2 cm Dilated	< 40 to 50% No collapse	> 10 mmHg Full (high filling pressure)						
Maximum IVC Diameter	Collapse Index (%) = 100 x (Max – Min Diameter) / Max Diameter	Estimated Right Atrial Pressure Estimated filling status																
< 2 cm Small	> 40 to 50% Collapses	< 10 mmHg Empty (low volume state)																
> 2 cm Dilated	< 40 to 50% No collapse	> 10 mmHg Full (high filling pressure)																

Cardiac PoCUS – Measurements and Quick Reference		
Assessment	Parameters	Values
RV thickness	Measured on subcostal view at level of tricuspid valve cordae.	Less than 0.5cm is normal
Mitral annular plane systolic excursion (MAPSE)	Surrogate of the left ventricular longitudinal function. Systolic excursion of the lateral mitral annulus Measured in M-mode	Normal range 12 +/- 2 mm
E-point septal separation (EPSS)	Measured from the anterior mitral valve leaflet to the ventricular septum in early diastole.	≥ 7 mm indicates EF <30%.
Tricuspid Annular Place Systolic Excursion (TAPSE)	Line is placed from the apex to the lateral tricuspid valve and the motion measured. A4C view / M-mode	Normal > 2cm
Valves: Aortic valve diameter	Measurements in PSLAX	Leaflets no more than 2mm Minimum tip separation 2cm in mid systole
Interventricular septal thickness	Diastolic M-mode recordings PSLAX	Normal: <1cm Men <0.9cm women